



PATIENT PRESENTING CLINICAL SIGNS

Moo Gilbert History: Intermittent vomiting since May. Weight loss, hyporexia.
Physical Examination: Thin, grade 4/6 heart murmur. Cardiology consult normal.

SPECIES
Feline Urinalysis: SG 1.035, 2+ protein, 1+ bilirubin.
Previous Fecal Analysis: Negative.

BREED
DSH Previous CBC: Lymphopenia.
Serum Biochemistry: Low albumin, elevated globulins. FIV/FelV negative. Maldigestion profile pending.

SEX
MN Radiographic Findings: Normal.

AGE ULTRASONOGRAPHIC EXAMINATION OF THE ABDOMEN

10 years

Urinary System

WEIGHT
10.4 # Full urinary bladder with a normal thickness and appearance of the wall. Normal anechoic urine with no sediment evident. Uroliths present.
Normal trigone area, proximal urethra, and iliac blood vessels.
Normal iliac lymph nodes. Ureters not visualized.

Normal size of the left kidney (3.6 cm), right renomegaly (right 4.9 cm) with increased echogenic appearance, some loss of cortico-medullary differentiation and normal pelvis and capsule. Focal cortical cyst in the left kidney.

IMAGING PERFORMED BY Reproductive System

Dr Megan Cassels-Conway, DVM N/A.

Adrenal Glands

HOSPITAL NAME
Central Broward Animal Hospital Normal shape, echogenic appearance, size. Left 0.85 x 0.5 cm, right 0.74 x 0.43 cm.

Spleen

REFERRING VET
Dr Oms, DVM Normal size and echogenic appearance. Smooth homogenous parenchyma, regular curvilinear capsule, and normal vasculature. No evidence of inflammatory, neoplastic, infarction, or infiltrative changes noted.

INVOICE Liver

303139 Normal size, echogenic appearance, portal markings, and curvilinear capsule. No nodules or masses evident. Full gall bladder containing normal anechoic bile. Normal appearance and thickness of the gall bladder wall. Normal bile duct.

DATE

7/21/22



PATIENT *Gastrointestinal*

Moo Gilbert Normal appearance of the stomach, duodenum, small intestine, ileo-cecal junction, and colon with no loss of layering, normal wall thickness and peristaltic activity, and no distension of the lumen. Ingesta within the stomach.

SPECIES

Feline *Pancreas*

BREED Enlarged and irregular with a hypoechogenic echogenic appearance. Hyperechogenic appearance of the mesentery and fat surrounding the pancreas.

DSH

Free Abdomen

SEX

No mesenteric lymphadenomegaly.
No ascites.

MN

AGE

ULTRASONOGRAPHIC FINDINGS

10 years

Primary Findings:

WEIGHT

- Pancreatitis.
- Right renomegaly.

10.4 #

Secondary Findings:

- Urinary bladder sediment.

INTERPRETED BY

Remo Lobetti, BVSc,
MMedVet (Med), PhD, Dipl.
ECVIM

INTERPRETATION OF THE FINDINGS & FURTHER RECOMMENDATIONS

The appearance of the pancreas is consistent with pancreatitis, with emerging neoplasia, a differential diagnosis.

IMAGING PERFORMED BY

Dr Megan Cassels-Conway,
DVM

Although the appearance of the right kidney may be an incidental finding, hypertensive nephropathy, emerging lymphoma, and granulomatous disease needs to be considered.

HOSPITAL NAME

Central Broward Animal
Hospital

Further assessment would be blood pressure, UPC ratio, fPL/PSL assay, and possibly FNA cytology of the right kidney and pancreas.

REFERRING VET

Dr Oms, DVM

Specific therapy would be dependent on an etiological diagnosis.

INVOICE

303139

DATE

7/21/22



PATIENT IMAGES

Moo Gilbert **Liver**

SPECIES

Feline

BREED

DSH

SEX

MN

AGE

10 years

WEIGHT

10.4 #

INTERPRETED BY

Remo Lobetti, BVSc,
MMedVet (Med), PhD, Dipl. ECVIM

IMAGING PERFORMED BY

Dr Megan Cassels-Conway,
DVM

HOSPITAL NAME

Central Broward Animal
Hospital

REFERRING VET

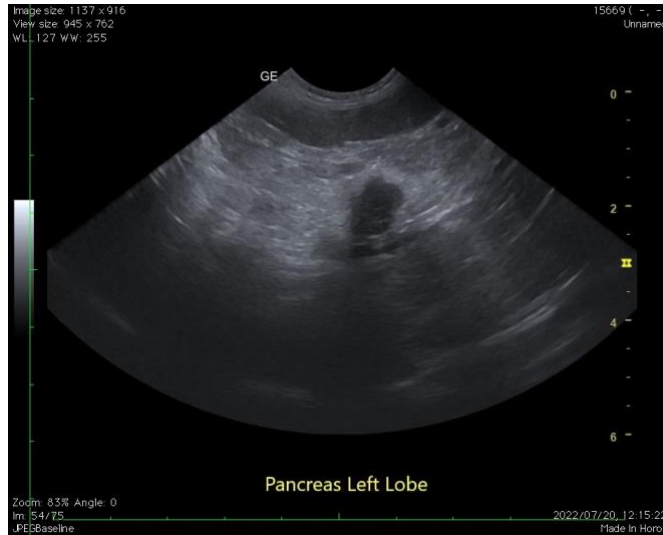
Dr Oms, DVM

INVOICE

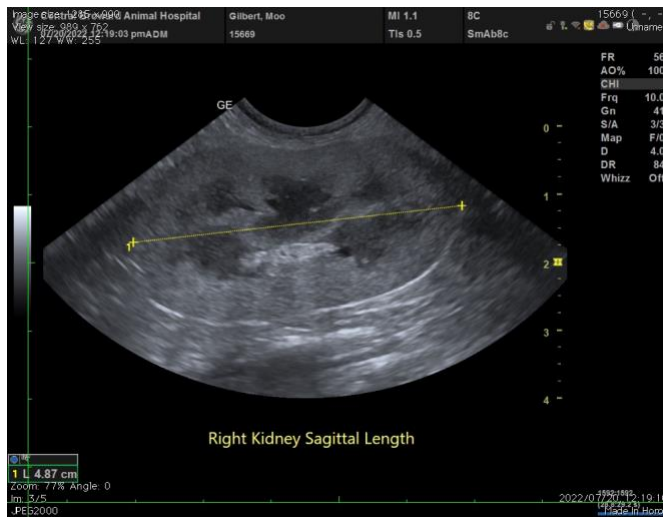
303139

DATE

7/21/22



Right kidney



The information and recommendations provided are based on the images presented by the referring veterinarian. No evaluation can be communicated regarding pathology that was not visible in the image/video clips provided.

Thank you for this referral. If the clinical or image interpretation does not parallel your findings or if I can be of any further assistance, please contact me.

Remo Lobetti, BVSc, MMedVet (Med), PhD, Dipl. ECVIM (Internal Medicine)
rlobetti@mweb.co.za